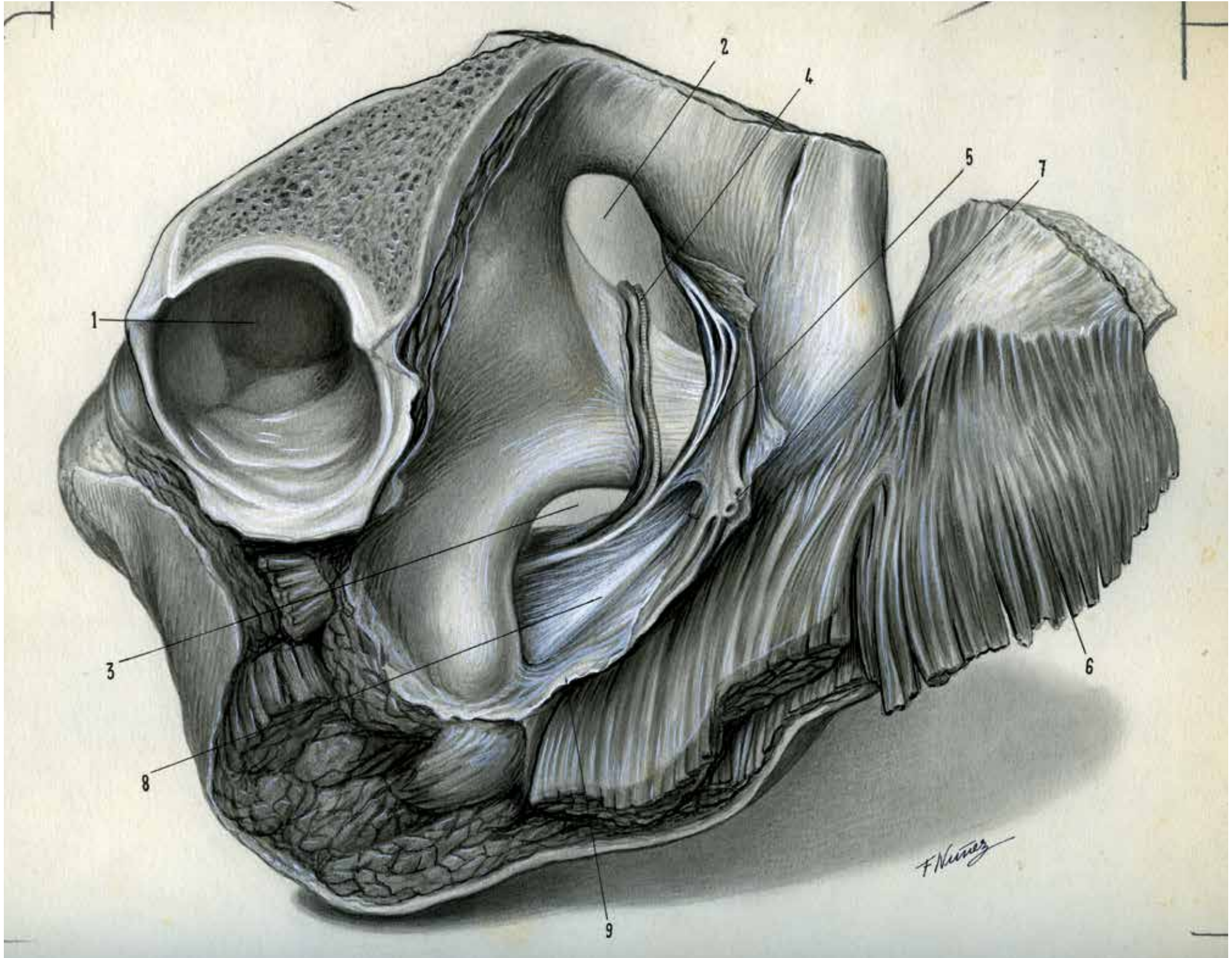

13
Mixed media on paper
22 x 30 cm
ca. 1943

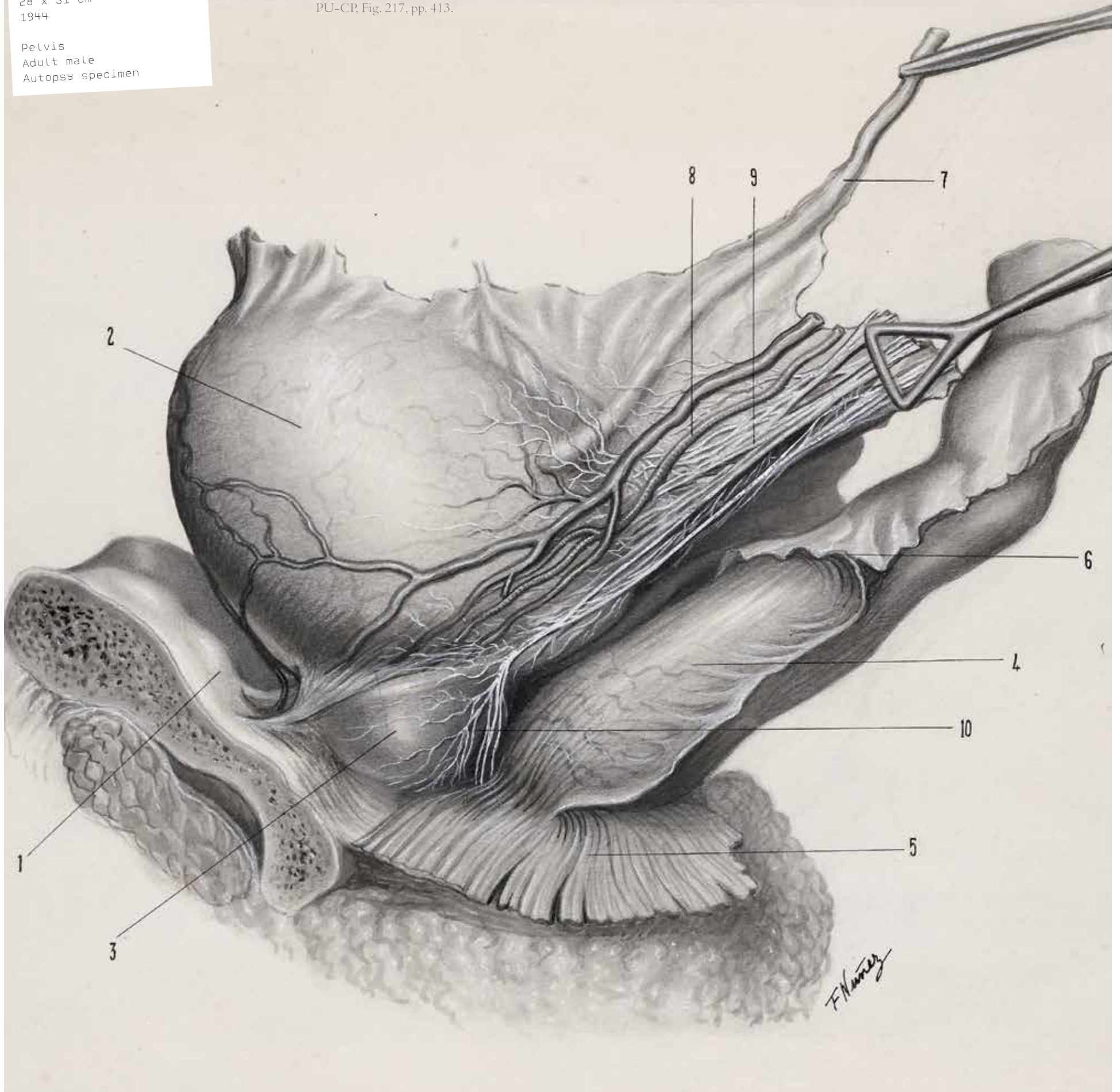
Pelvis
Adult male
Autopsy specimen

Acetabulum. Greater and lesser sacrosclatic foramina. Sacrotuberous ligament.
Internal pudendal nerve and vessels. Fibers of the gluteus maximus muscle.
PU-CR, Fig. 187, pp. 369.

14
 Mixed media on paper
 28 x 31 cm
 1944

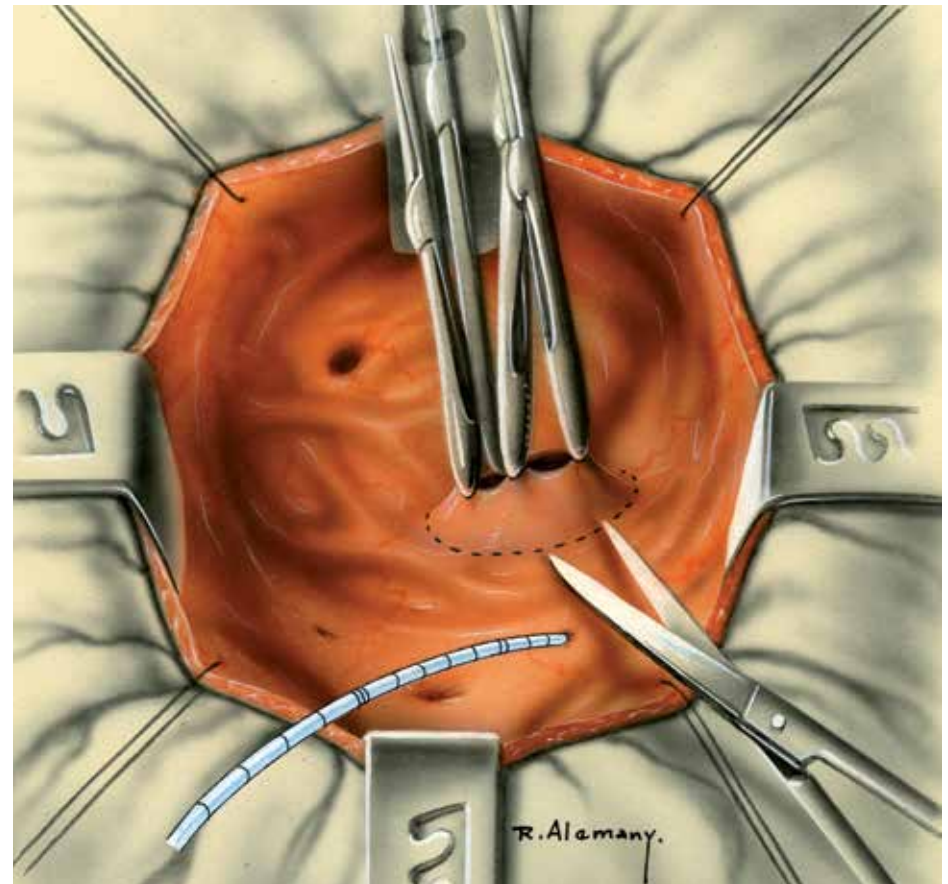
Pelvis
 Adult male
 Autopsy specimen

Left neural pelvic plexus. Neurovascular prostate bundles. Bladder and left ureter. Peritoneum. Rectum. Levator ani muscle. Ischiopubic ramus.
 PU-CR, Fig. 217, pp. 413.



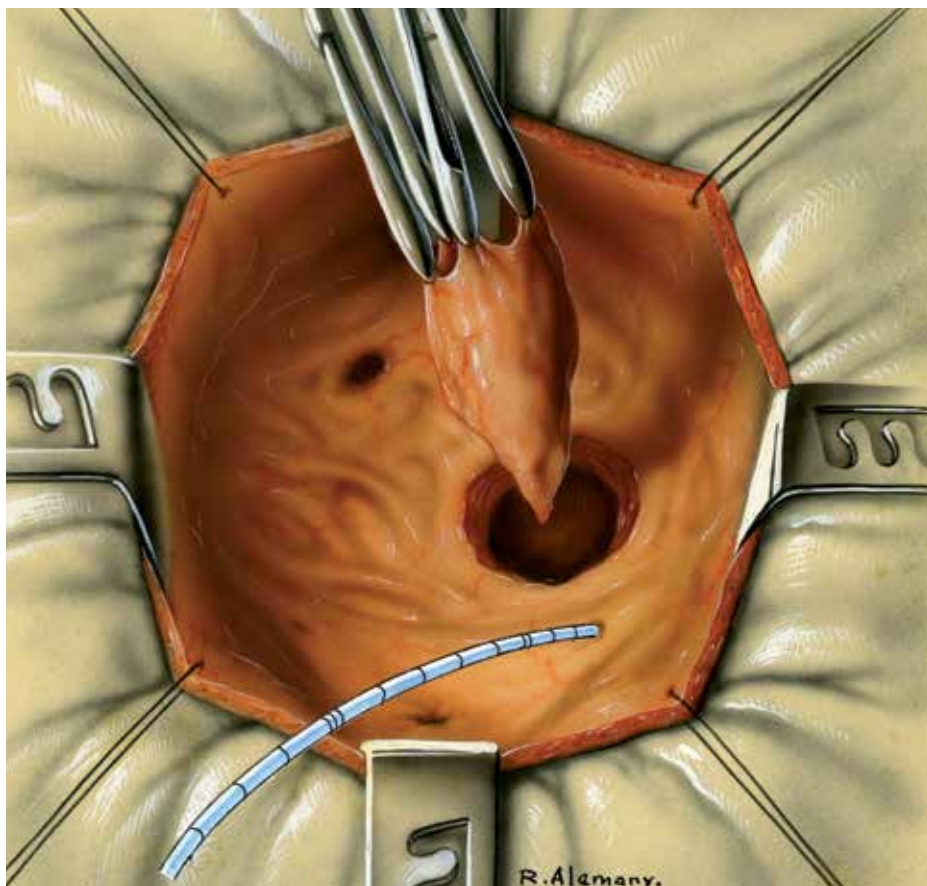
TRANSVESICAL DIVERTICULECTOMY

Excision of bladder diverticula after opening the bladder



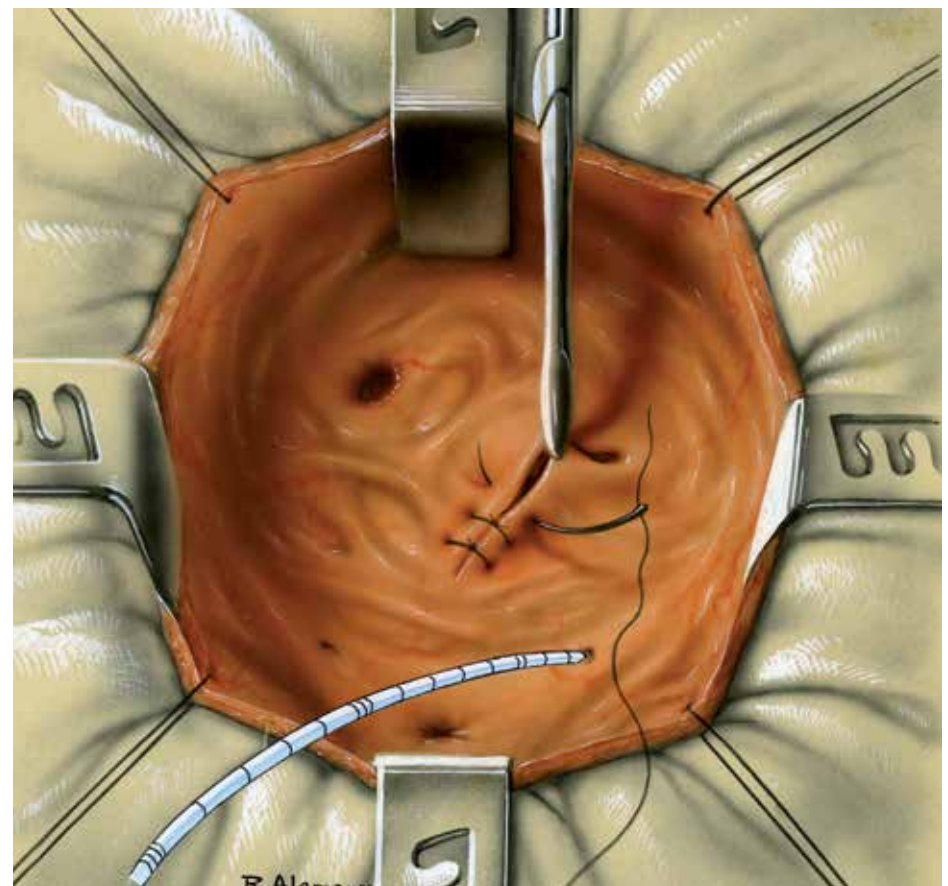
73
Mixed media on paper
21 x 17 cm
ca. 1947

Incision around the opening of the diverticulum. Left ureteral catheter.



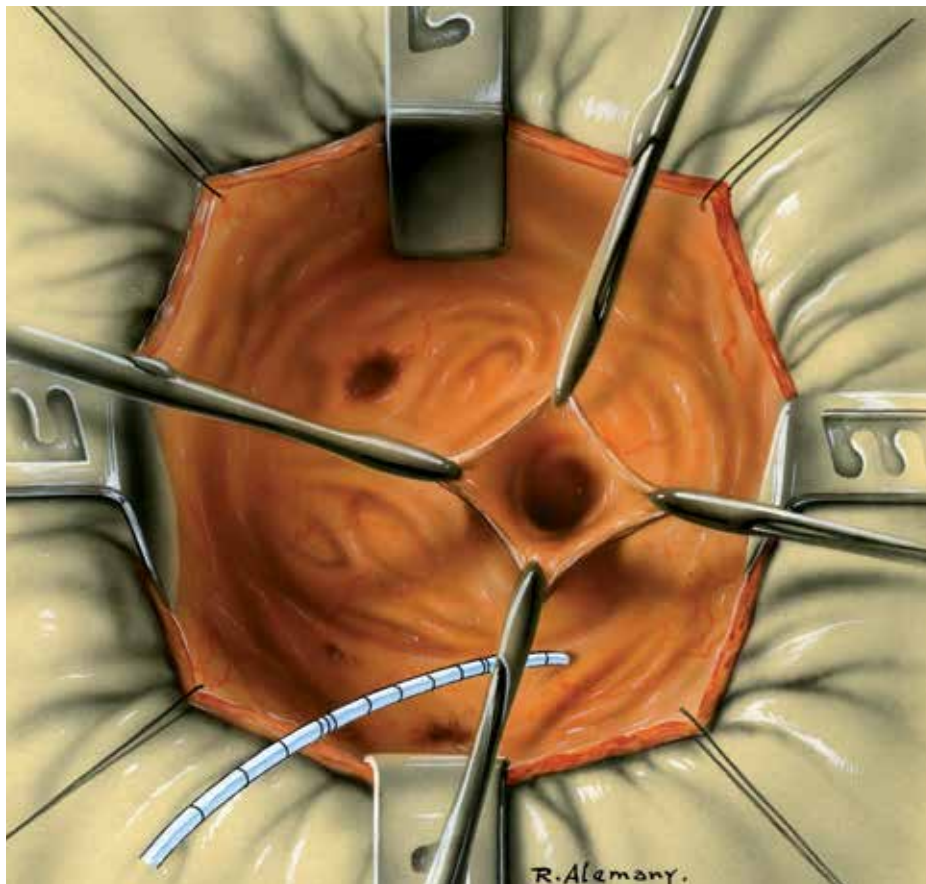
76
Mixed media on paper
21 x 16 cm
ca. 1947

Excision of the diverticular sac.
Left ureteral catheter.



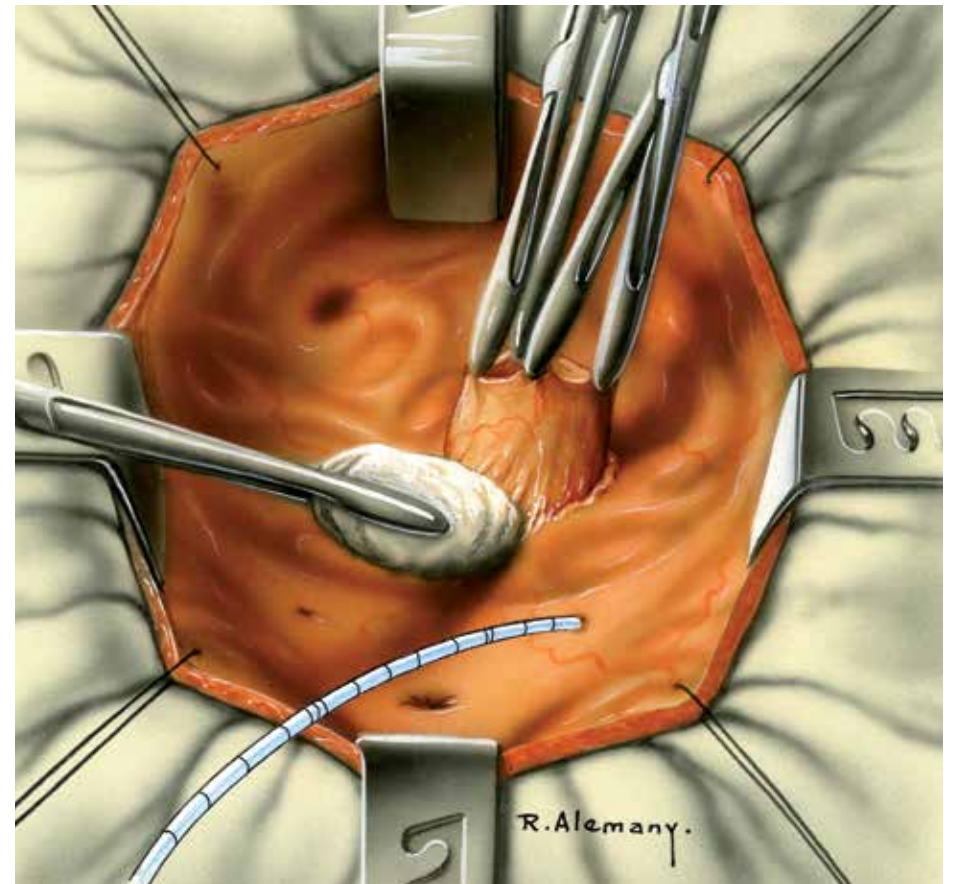
77
Mixed media on paper
21 x 16 cm
ca. 1947

Bladder wall suture with loose stitches.
Left ureteral catheter.



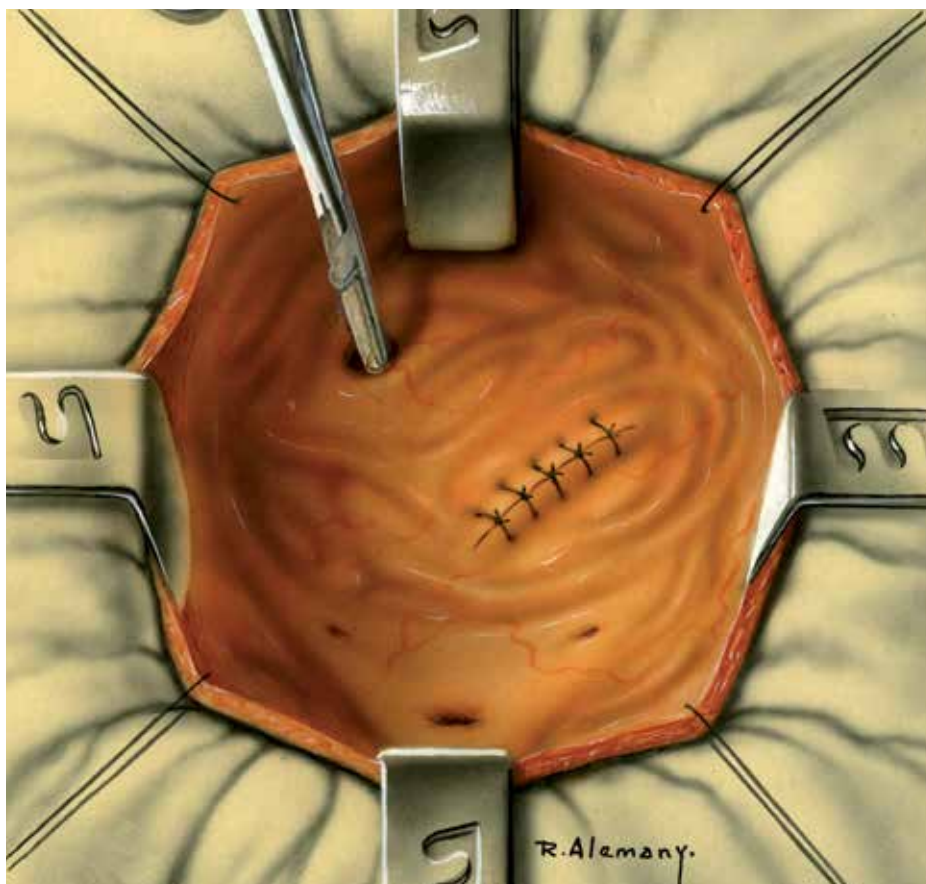
74
Mixed media on paper
21 x 17 cm
ca. 1947

Diverticulum drawn upward.
Left ureteral catheter.



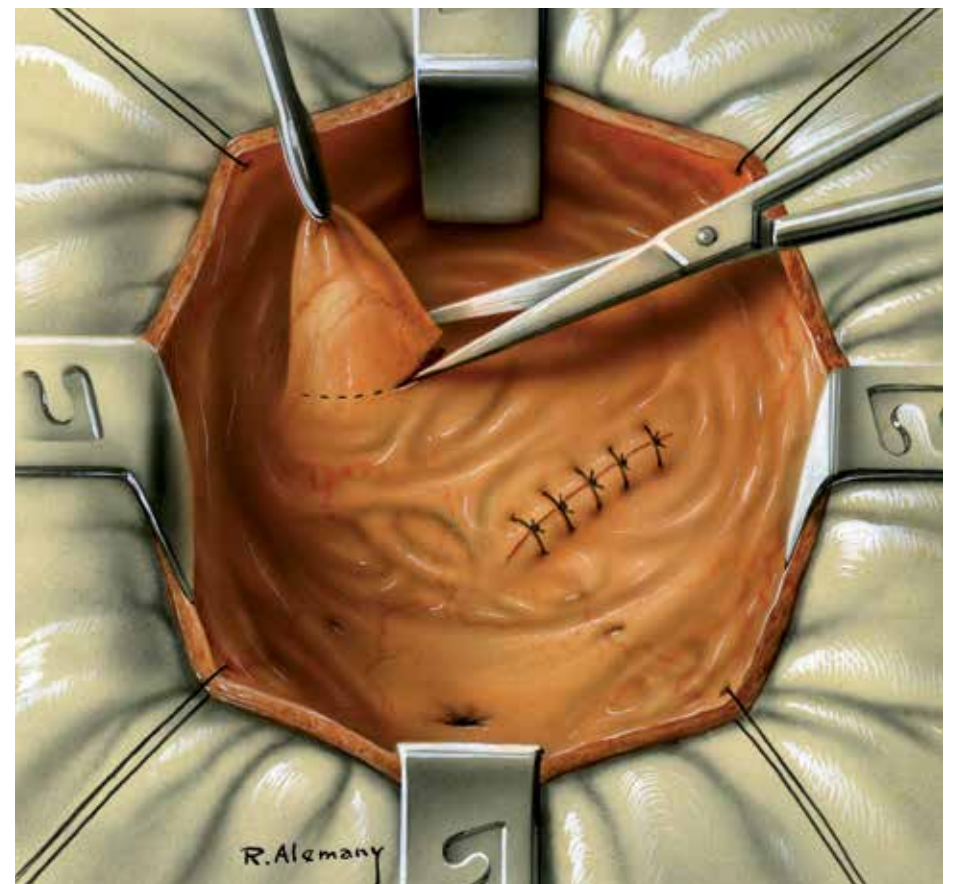
75
Mixed media on paper
21 x 17 cm
ca. 1947

Blunt dissection of the diverticulum.
Left ureteral catheter.



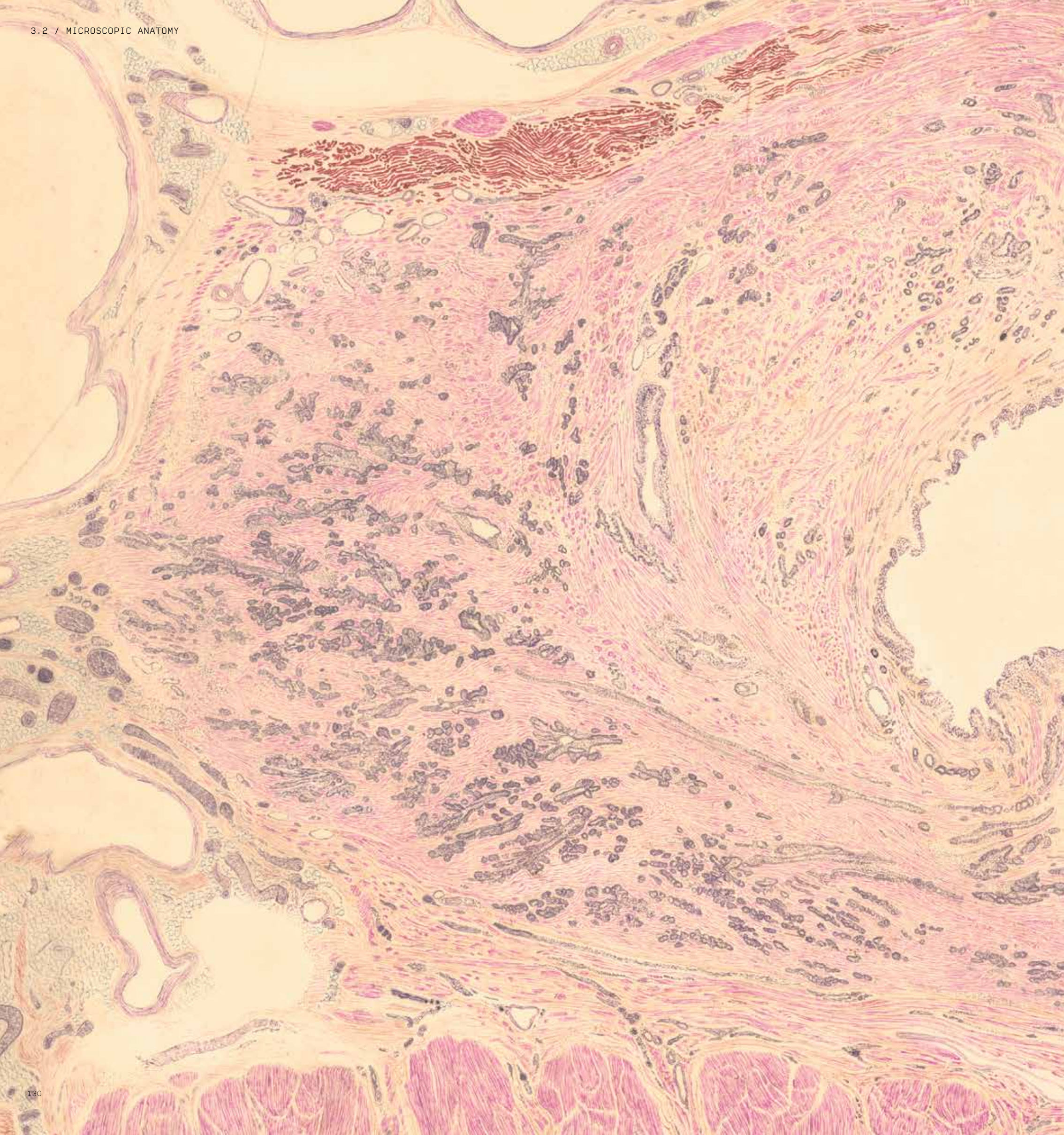
78
Mixed media on paper
21 x 16 cm
ca. 1947

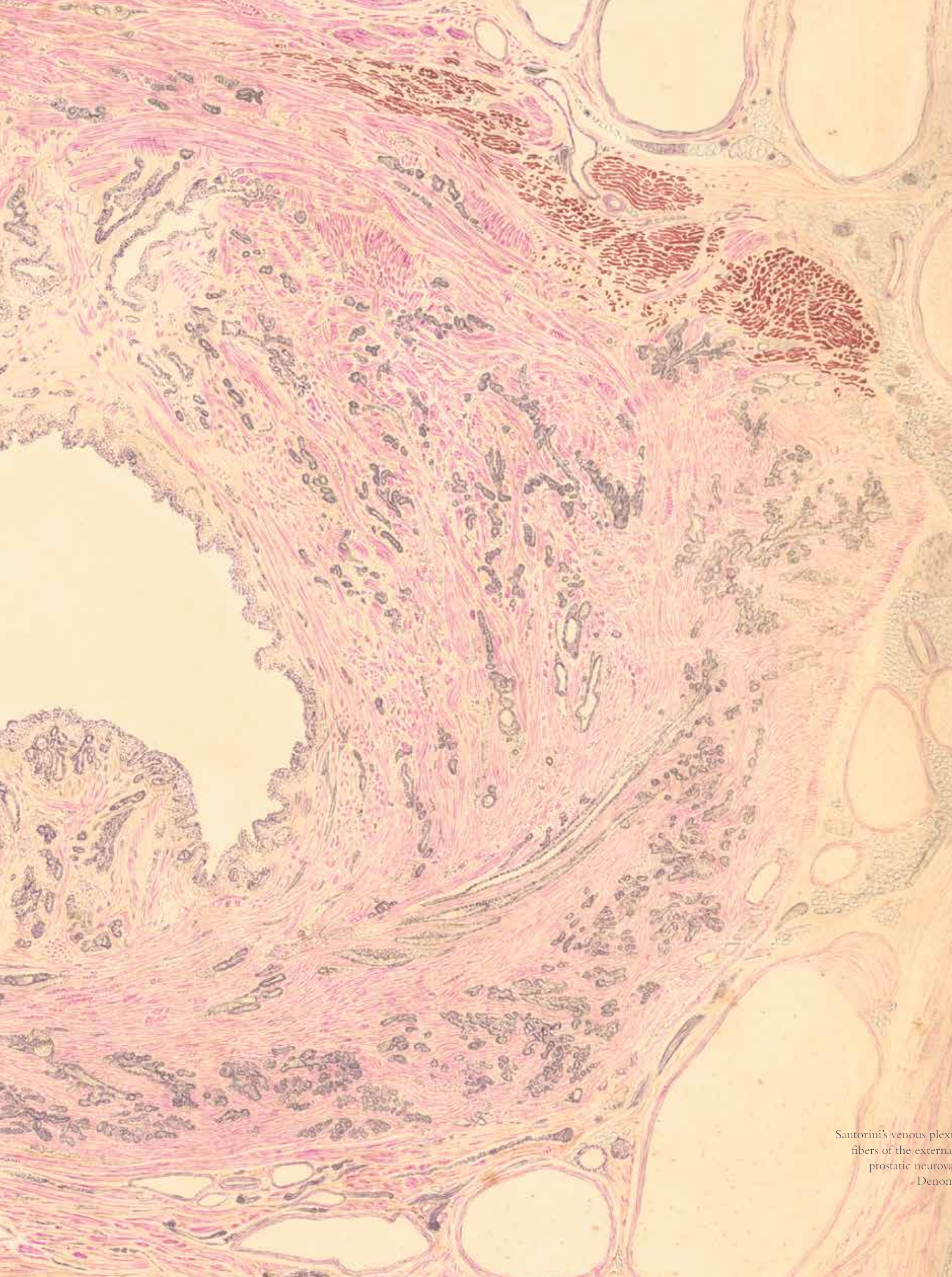
Exploration of the right posterosuperior
diverticulum.



79
Mixed media on paper
21 x 16 cm
ca. 1947

Traction and section of diverticular sac.





98
P. Capdevila
Indian ink on paper
57 x 77 cm
ca. 1946

Prostate
Five-year-old male
Oblique coronal section
HE stain

Santorini's venous plexus. Prostate. Urethral crest. Ventral fibers of the external urethral sphincter. Posterolateral prostatic neurovascular bundles. Endopelvic fascia. Denonvilliers fascia. Anterior rectal wall.